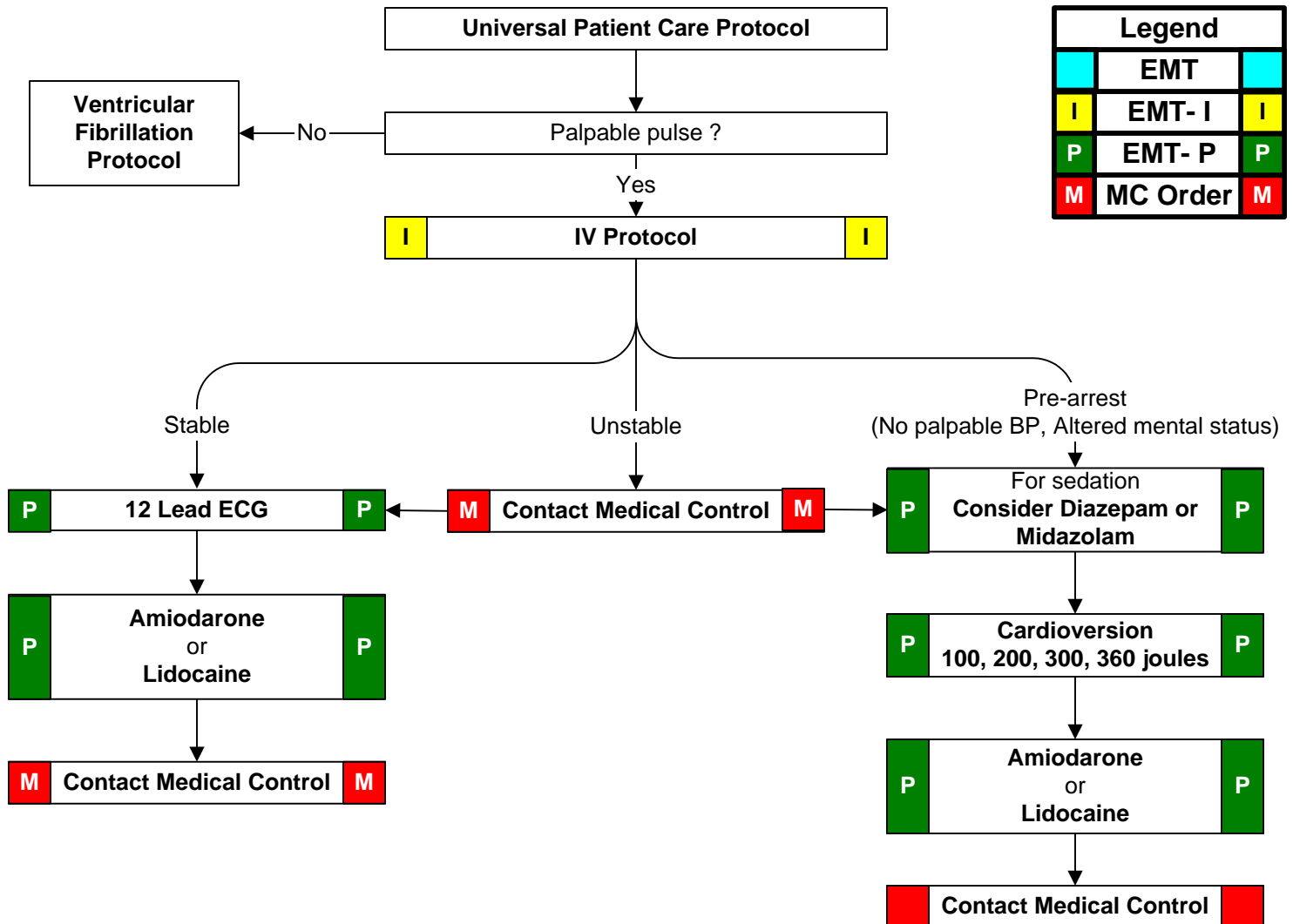


History: <ul style="list-style-type: none"> • Past medical history / medications, diet, drugs. • Syncope / near syncope • Palpitations • Pacemaker • Allergies: lidocaine / novacaine 	Signs and Symptoms: <ul style="list-style-type: none"> • Ventricular tachycardia on ECG (Runs or sustained) • Conscious, rapid pulse • Chest pain, shortness of breath • Dizziness • Rate usually 150 - 180 bpm for sustained V-Tach 	Differential: <ul style="list-style-type: none"> • Artifact / Device failure • Cardiac • Endocrine / Metabolic • Drugs • Pulmonary
-------------------------------------------------------------------------------------------------------------------------------------------------------------------------------------------------------------------------------------------------	------------------------------------------------------------------------------------------------------------------------------------------------------------------------------------------------------------------------------------------------------------------------------------------------	---------------------------------------------------------------------------------------------------------------------------------------------------------------------------------------------------------------------------------



Pearls: <ul style="list-style-type: none"> • Exam: Mental Status, Skin, Neck, Lung, Heart, Abdomen, Back, Extremities, Neuro • For witnessed / monitored ventricular tachycardia, try having patient cough or deliver a precordial thump. • Polymorphic V-Tach (Torsades de Pointes) may benefit from the administration of magnesium sulfate.
